

REVIEW ARTICLE

CURRENT CONCEPTS

Benign Breast Disorders

Richard J. Santen, M.D., and Robert Mansel, M.D., Ph.D.

HORMONES AND GROWTH FACTORS ACT ON STROMAL AND EPITHELIAL cells to regulate the development, maturation, and differentiation of mammary-gland cells.^{1,2} Broadly summarized, estrogen mediates the development and elongation of ductal tissue, progesterone facilitates ductal branching and lobulo-alveolar development, and prolactin regulates the production of milk protein. At puberty, estradiol and progesterone levels increase to initiate breast development. A complex tree-like structure results, comprising 5 to 10 primary milk ducts that originate at the nipple, 20 to 40 segmental ducts, and 10 to 100 subsegmental ducts that end in glandular units called terminal-duct lobular units.³ In the adult breast, cyclic changes occur during the menstrual cycle that result in an increased rate of cell proliferation during the luteal phase.⁴ An increase in breast size by up to 15 percent may occur during this phase.⁴ At menopause, the total number of lobules diminishes.

From the Department of Medicine, University of Virginia Health Sciences Center, Charlottesville (R.J.S.); and the Department of Surgery, University of Wales College of Medicine, Cardiff, Wales, United Kingdom (R.M.). Address reprint requests to Dr. Santen at the University of Virginia, P.O. Box 801416, Charlottesville, VA 22908, or at rjs5y@virginia.edu.

N Engl J Med 2005;353:275-85.

Copyright © 2005 Massachusetts Medical Society.

CHANGES IN THE NORMAL BREAST

The morphologic features of the breast undergo substantial change between early adolescence and menopause.⁵ The spectrum of normal histologic features ranges from a predominance of ducts, lobules, and intralobular and interlobular stroma to features that exhibit mainly patterns of fibrous change and cyst formation, formerly called fibrocystic disease of the breast. The term “fibrocystic changes” is now preferred, since in up to 50 to 60 percent of women without breast disease, this histologic pattern may be evident.⁶ The term “fibrocystic changes” implies that women with lumpy breasts or breasts with nondiscrete nodules do not have breast disease. The fibrocystic changes detected clinically entail no increased risk of breast cancer.

In women between adolescence and the mid-20s, the lobules and stroma in the breast may respond to hormonal stimuli in an exaggerated fashion with the development of single and multiple palpable fibroadenomas.⁷ In autopsy series, 15 to 23 percent of women in this age group were found to have fibroadenomas, whereas specialized clinics have found 7 to 13 percent among female patients in this age group and epidemiologic studies have found 2.2 percent.^{5,8,9} In the third and fourth decades of life, the degree of diffuse palpable nodularity may increase. In histologic terms, this increase represents adenosis — that is, enhancement of the amount of normal lobular tissue. The stroma may also undergo hypertrophy, resulting in palpable areas of ill-defined fullness, frequently in the axillary tail. In women between the middle of the fourth decade of life and menopause, glandular tissue may undergo further hypertrophy in association with an increase in stromal tissue. A higher prevalence of cyst formation is associated with late menopause, the use of hormone-replacement therapy, and a thin body composition.^{8,10}

CLASSIFICATION OF BENIGN BREAST LESIONS

In a practical classification, breast lesions that do not increase the risk of breast cancer are distinguished from those that confer a small increase in risk (relative risk, 1.5 to 2.0)

or a moderate increase (relative risk, >2.0) (Table 1).¹² The levels of risk have been established by means of long-term follow-up, and the specific lesions were defined by a consensus conference.^{12,13} An important basis of the classification is the degree of cellular proliferation.¹²⁻¹⁴

CAUSAL FACTORS
IN BENIGN BREAST DISORDERS

Clinical observations of women receiving estrogens and antiestrogen drugs suggest that hormonal events play a causative role in the development of benign lesions. Among postmenopausal women receiving estrogens with or without progestins for more than eight years, the prevalence of benign breast lesions increased by a factor of 1.70 (95 percent confidence interval, 1.06 to 2.72).¹⁵ The antiestrogen drug tamoxifen, when used in the prevention of breast cancer, is associated with a reduction of 28 percent in the prevalence of benign breast lesions (relative risk, 0.72; 95 percent confidence interval, 0.65 to 0.79), including those classified as adenosis, cysts, mammary-duct ectasia, and hyperplasia.¹⁶

Underlying and acquired genetic changes are also associated with benign breast lesions (Fig. 1). Loss of heterozygosity, as a result of deletions of small segments of DNA,¹⁸⁻²² is commonly found in benign breast lesions. Lesions are frequently multifocal, with each lesion exhibiting loss of heterozygosity of different regions of DNA. Women with mutations in the *BRCA1* or *BRCA2* genes have a high frequency of multiple benign or malignant breast lesions on meticulous examination of specimens obtained from bilateral mastectomy.²³ These findings support the current theory of an underlying predisposition to mutations in some patients as the cause of multiple breast lesions. This phenomenon (i.e., a predisposition to mutations) has been termed a field effect and, more recently, a mutator phenotype.²⁴

PROGRESSION
TO MALIGNANT DISEASE

By analogy to the linear model of the development of colon cancer,²⁵ breast lesions are believed by many investigators to progress in a linear fashion from usual ductal hyperplasia (ductal hyperplasia with-

Table 1. Classification of Benign Breast Lesions on Histologic Examination, According to the Relative Risk of Breast Cancer.

Risk	Proliferation	Histologic Findings
No increase	Minimal	Fibrocystic changes (within the normal range): cysts and ductal ectasia (72%), mild hyperplasia (40%), nonsclerosing adenosis (22%), and periductal fibrosis (16%)*; simple fibroadenoma (15–23%)†; and miscellaneous (lobular hyperplasia, juvenile hypertrophy, and stromal hyperplasia) Benign tumors: hamartoma, lipoma, phyllodes tumor,‡ solitary papilloma, neurofibroma, giant adenoma, and adenomyoepithelioma Traumatic lesions: hematoma, fat necrosis, and lesions caused by penetration by a foreign body Infections: granuloma and mastitis Sarcoidosis Metaplasia: squamous and apocrine Diabetic mastopathy
Small increase (relative risk, 1.5–2.0)	Proliferative without atypia	Usual ductal hyperplasia, complex fibroadenoma (containing cysts >3 mm in diameter, sclerosing adenosis, epithelial calcifications, or papillary apocrine changes), papilloma or papillomatosis, radial scar, and blunt duct adenosis
Moderate increase (relative risk, >2.0)	Proliferative with atypia	Atypical ductal hyperplasia and atypical lobular hyperplasia

* Percentages indicate the percentage of breasts examined at autopsy in which the lesion was found. Data are from Sandison.¹¹

† Data are from Goehring and Morabia.⁸

‡ Most phyllodes tumors are considered to be benign fibroepithelial tumors, but some have malignant clinical and histologic features.

out atypia) or from unfolded lobules²⁰ to atypical ductal hyperplasia and then to ductal carcinoma in situ and invasive cancer. Several biologic and molecular changes (Fig. 1) have been observed in association with this progression, but causal relationships have not been established.

CLINICAL FEATURES OF BENIGN BREAST DISEASE

BREAST PAIN

Cyclic breast pain usually occurs during the late luteal phase of the menstrual cycle, in association with the premenstrual syndrome or independently,²⁶⁻³¹ and resolves at the onset of menses (Table 2).^{26,27} In a study of 1171 healthy premenopausal American women, 11 percent had moderate-to-severe cyclic breast pain and 58 percent had mild discomfort.^{28,31} Breast pain interfered with usual sexual activity among 48 percent of the patients, and among others it interfered with physical activi-

ties (37 percent), social activities (12 percent), and school activities (8 percent).^{28,31} Whether caffeine, iodine deficiency, alterations in levels of fatty acid in the breast, fat intake in the diet, or psychological factors have a causative role in cyclic breast pain has not been established.^{32,33}

Noncyclic breast pain is unrelated to the menstrual cycle. Detection of focal tenderness is helpful diagnostically and suggests a tender cyst, rupture through the wall of an ectatic duct, or a particularly tender area of breast nodularity. Acute enlargement of cysts and periductal mastitis may cause severe, localized pain with a sudden onset.

NONBREAST PAIN

Pain arising from the chest wall may be mistakenly attributed to the breast. Pain that is limited to a particular area and characterized as burning or knife-like in nature may arise from the chest wall. Several distinct types of pain can be distinguished, including localized or diffuse lateral chest-wall pain, radicular

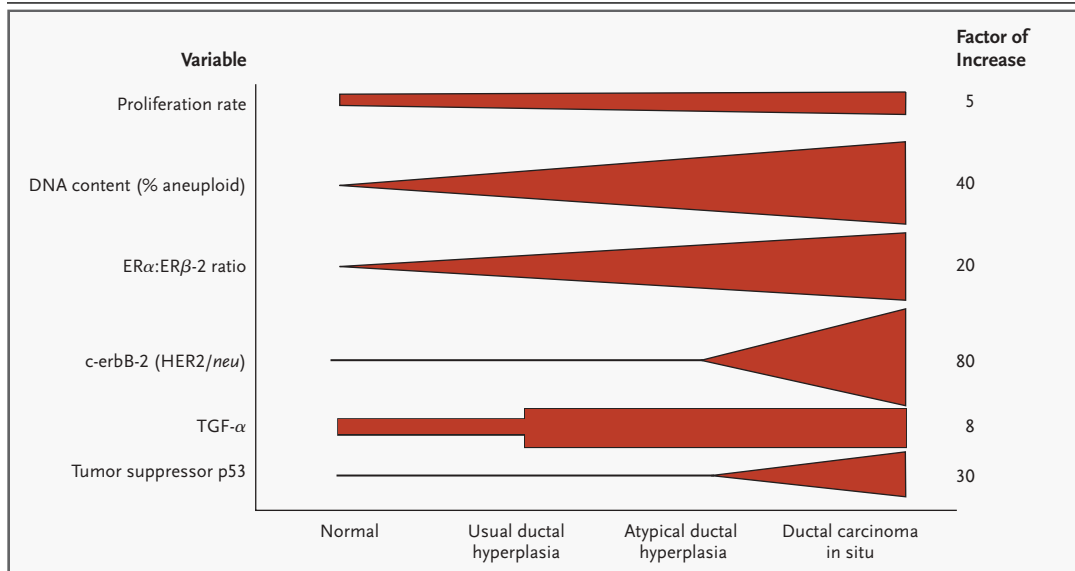


Figure 1. Progression from a Benign to a Malignant Lesion.

Progression to malignant breast disease is associated with the accumulation of an increasing number of genetic mutations. Numbers at the right are factors by which the items listed on the left are increased in women with ductal carcinoma in situ. The rate of proliferation increases by a factor of five when benign breast tissue is compared with ductal carcinoma in situ. The DNA content, as represented by aneuploidy (more or less DNA than would be expected for the presence of 46 chromosomes) gradually increases. Aneuploidy is commonly present in ductal carcinoma in situ. Several studies have shown that levels of estrogen receptor α (ER α) increase, and one large recent study showed a reduction in levels of estrogen receptor β (ER β).¹⁷ The oncogene for transforming growth factor α (TGF- α) increases concomitantly with the appearance of hyperplasia. There is an increase in c-erbB-2 (HER2/*neu*) and in mutations of the tumor-suppressor gene p53 only in ductal carcinoma in situ. For references for data in this figure, see the Supplementary Appendix, available with the full text of this article at www.nejm.org.

Table 2. Common Benign Breast Disorders in Women.

Symptom or Finding	Possible Causes or Disorders
Breast pain	
Cyclic pain	Hormonal stimulation of normal breast lobules before menses
Noncyclic pain	Stretching of Cooper's ligaments Pressure from brassiere Fat necrosis from trauma Hidradenitis suppurativa Focal mastitis Periductal mastitis Cyst Mondor's disease (sclerosing periphlebitis of breast veins)
Nonbreast pain	
Chest-wall pain	Tietze's syndrome (costochondritis) Localized lateral chest-wall pain Diffuse lateral chest-wall pain Radicular pain from cervical arthritis
Non-chest-wall pain	Gallbladder disease Ischemic heart disease
Nipple discharge	
Presence of galactorrhea	
From multiple ducts bilaterally	Hyperprolactinemia from pituitary tumor, hypothyroidism, drugs*
Absence of galactorrhea	
From one duct — elicited or spontaneous and bloody, with occult blood, or serosanguineous	Intraductal papilloma Ductal carcinoma in situ Paget's disease of breast
From multiple ducts — elicited and bloody or nonbloody, bilateral, black or clear	Fibrocystic changes Ductal ectasia
Discrete solitary lump	
Age <30 yr	
Firm, rubbery lump	Most common lesion: fibroadenoma
Age 30–50 yr	
Firm, discrete lump	Most common lesions: fibroadenoma, cyst, fibrocystic changes, usual ductal hyperplasia, atypical ductal hyperplasia, atypical lobular hyperplasia†
Age >50 yr	
Firm, discrete lump	Most common lesions: cyst, ductal carcinoma in situ, invasive cancer
Diffuse lumpiness ("lumpy-bumpy")	
Absence of discrete lump	Fibrocystic changes

* Data on drugs with galactorrhea as an adverse effect are listed in standard textbooks.

† Usual ductal hyperplasia, atypical ductal hyperplasia, and atypical lobular hyperplasia may be detected incidentally in female patients undergoing biopsy of masses with other causes, such as fibroadenomas and fibrocystic changes.

pain from cervical arthritis, and pain from Tietze's syndrome (costochondritis).

NIPPLE DISCHARGE

Among female patients referred to physicians because of symptoms of breast disorder, 6.8 percent have nipple discharge. Although this symptom is particularly distressing to the patient, only 5 percent of these patients are found to have serious underlying disease.³⁴ Nipple discharge is considered to be pathologic if it is spontaneous, arises from a single duct, is persistent, and contains gross or occult blood. Age is an important factor with respect to the risk of malignant disease. In one series, among women with nipple discharge as their only symptom who were found to have cancer, 3 percent were younger than 40 years of age, 10 percent were between 40 and 60 years, and 32 percent were older than 60 years.³⁵

FOCAL AND DIFFUSE BREAST LUMPS

Discrete lesions detected by palpation or on routine mammography are different entities in women who are less than 30 years of age, 31 to 50 years, or older than 50 years. On a statistical basis, 9 of 10 new nodules in premenopausal women are benign (Table 1). Diffuse symmetrical lumpiness is commonly found on physical examination and is associated with fibrocystic changes on histologic examination.

ABNORMALITIES ASSOCIATED WITH AN INCREASED RISK OF BREAST CANCER

Several pathologic entities are associated with an enhanced risk of breast cancer³⁶⁻³⁸ (Table 1). A recent report suggests that there is a slight increase in the risk of breast cancer among women more than 50 years of age with benign lesions that are in the lower category of risk: cyst, adenosis, mammary-duct ectasia, fibrosis, metaplasia, fibroadenoma, mild-to-moderate or florid hyperplasia without atypia, and papilloma.³⁸ This study combined two groups of women in the lower category of risk: those with proliferative disease without atypia and those with nonproliferative disease (Table 1). A large study reported elsewhere in this issue of the *Journal*¹³ found an increased risk of breast cancer only among women with proliferative disease. Among women with nonproliferative lesions, only those with a strong family history of breast cancer were at increased risk.

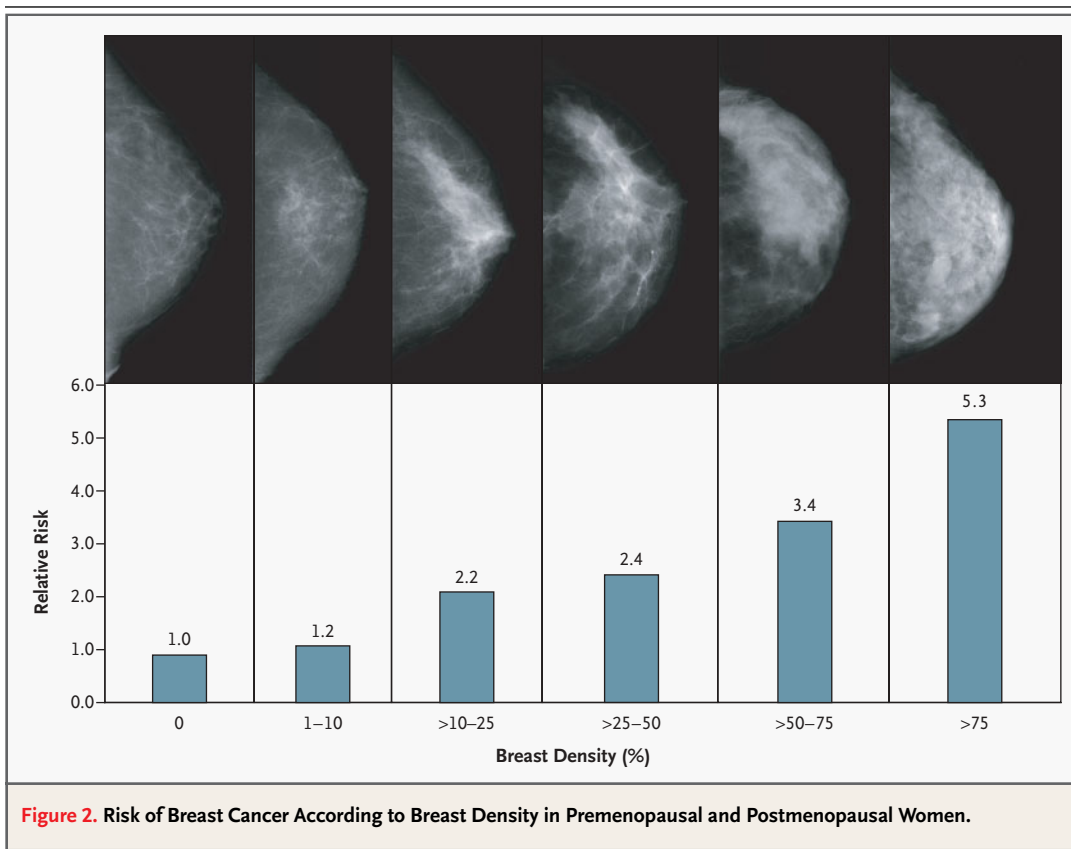
Breast density on mammographic screening is also a risk factor, with an increase in relative risk by a factor of five for the highest density³⁹⁻⁴² (Fig. 2). Dense breasts contain a higher proportion of stromal and glandular tissue as well as an increased number of lesions classified as usual ductal hyperplasia and atypical ductal hyperplasia.⁴⁰ According to classic studies in twins, heritability accounts for approximately 60 percent of the variation in breast density.⁴²

The risk of breast cancer is also increased in association with high plasma levels of free estradiol and testosterone in postmenopausal women,^{43,44} weight gain of 20 kg (44 lb) or more after menopause, early menarche, late menopause, late child-bearing, and a family history of breast cancer.⁴⁵ However, it is not known whether the increased risk associated with breast density or specific histologic lesions adds to these other known risks or whether these factors are merely dependent variables.^{44,45} *BRCA1* carriers have a 65 percent probability (95 percent confidence interval, 44 to 78 percent) of developing breast cancer by 70 years of age, and *BRCA2* carriers have a 45 percent probability (95 percent

confidence interval, 31 to 56 percent).⁴⁶ Studies are under way to evaluate the use of nipple aspiration and ductal lavage as additional means of risk stratification.⁴⁷ Currently, the Gail and Claus models are commonly used as practical means of estimating the risk of breast cancer, but these models use only a limited number of variables and are not powerful in predicting disease.^{48,49}

PRACTICAL MANAGEMENT

A detailed history and physical examination are used to evaluate systematically the entire breast and the chest wall and should focus on areas related to the patient's symptoms (Table 3). The sensitivity and specificity of the clinical breast examination are estimated to be 54 percent and 94 percent, respectively, and depend on the thoroughness and technique of the examiner.⁵⁰ Diagnostic studies may then be ordered. The "triple test" of lumps includes palpation, imaging, and percutaneous biopsy (i.e., core needle biopsy or fine-needle aspiration). Mammography, often in conjunction with ultrasonographic examination,⁵¹⁻⁵⁴ is required for evaluation of dis-



crete palpable lesions in women more than 35 years of age; ultrasonography provides an optional substitute among younger women. Round dense lesions detected on mammography often are cysts that require ultrasonographic examination to distinguish them from solid lesions.

For solid lesions, core needle biopsy directed with the use of radiographic or ultrasonographic techniques provides highly discriminative information with regard to the presence or absence of malignant disease. In core needle biopsy, a large cutting needle is used with a spring-loaded, automated biopsy instrument to obtain tissue specimens suitable for histologic analysis. Fine-needle aspiration yields cellular material suitable for cytologic evaluation, but the technique must be used by an experi-

enced cytopathologist and the specimen obtained is insufficient for diagnosis in up to 36 percent of cases in which there are nonpalpable lesions.⁵⁵

The roles of magnetic resonance imaging (MRI) and digital mammography in the evaluation of breast lesions are currently being investigated. Galactography (also called ductography) is useful in the detection of focal lesions within a single duct. Cytologic examination of nipple discharge is of limited value, with a sensitivity for detecting malignant disease of only 35 to 47 percent.^{34,56} In the treatment of all patients with benign breast disease, clinical judgment is required to provide the proper balance between the intense and frequent surveillance needed for some patients and the risk of overdiagnosis and treatment for others.

Table 3. Clinical Examination of a Patient with Benign Breast Disease.

<p>History</p> <p>Characterize symptoms</p> <p>Identify risk factors for breast cancer</p> <p>Age</p> <p> At menarche</p> <p> At first live birth</p> <p> Number of relatives with breast cancer or ovarian cancer</p> <p> Age at diagnosis</p> <p> Number of previous breast biopsies</p> <p> Presence of atypical hyperplasia or lobular carcinoma in situ on previous breast biopsy</p> <p> Weight gain after menopause</p> <p> Waist-to-hip ratio</p> <p> Results of bone-density testing</p> <p>If patient is postmenopausal</p> <p> Age at menopause</p> <p> Duration of use of estrogen or progestin therapy</p> <p>Physical examination</p> <p>Palpate the four breast quadrants while patient is sitting and lying down</p> <p> Identify discrete lumps and examine for regional nodes</p> <p> Determine whether consistency is doughy with vague nodularity — findings consistent with fibrocystic changes</p> <p> Determine whether a discrete lesion has distinctly margined borders — a finding consistent with fibroadenoma</p> <p>Examine overlying skin, areola, and axilla</p> <p>Determine degree of symmetry (asymmetry suggests underlying disease)</p> <p>Examine nipple and seek to elicit discharge</p> <p> Determine whether galactorrhea is present</p> <p> Determine whether discharge is from one duct or from multiple ducts</p> <p> Determine whether discharge is viscous, watery, serosanguineous, grossly bloody, clear, blue-black, or green</p> <p> Determine whether occult blood is present</p> <p>Seek to elicit chest-wall pain</p> <p> Examine costochondral junctions (Tietze's syndrome)</p> <p> Examine lateral chest wall while patient is lying on her side (at 90 degrees), to move breast away from chest wall</p> <p> Compare pain elicited by squeezing breast tissue with pain elicited by palpation of chest wall</p>
--

TREATMENT

CYCLIC BREAST PAIN

The most important issue in the management of cyclic breast pain is to decide whether to treat. In the absence of a mass or discharge, mild symptoms warrant reassuring the patient regarding the absence of serious disease.⁵⁷ Among 85 percent of women evaluated in large referral clinics,⁵⁸ watchful waiting without treatment was considered acceptable after their anxiety about malignant disease was alleviated, whereas the remaining 15 percent requested treatment. Several clinics specializing in breast disorders administer tamoxifen and danazol for breast pain and have conducted randomized, placebo-controlled, clinical trials to demonstrate the efficacy of these strategies. Data on secondary end points from the International Breast Cancer Intervention Study, involving 7152 women who received tamoxifen for adjuvant therapy for breast cancer, provide additional evidence of the efficacy of this agent in relieving mastalgia.⁵⁹ Several other therapies are probably beneficial, on the basis of physiologic principles. Precise fitting of a brassiere to provide support for pendulous breasts may provide pain relief.⁶⁰ Lowering the dose of estrogens in the treatment of postmenopausal women or the addition of an androgen to estrogen-replacement therapy appears to be beneficial in reducing breast pain. The use of oral contraceptives has not been systematically studied, but preparations that contain low-dose estrogen (20 µg of ethinyl estradiol) and 19-nor progestins may produce relief.^{61,62}

No standard regimen for moderate-to-severe breast pain has been widely accepted. Initial recom-

mentations may include the use of mild analgesic agents such as acetaminophen, nonsteroidal anti-inflammatory drugs (NSAIDs), or aspirin.^{32,33,56,63-67} Other approaches include tamoxifen, at a dose of 10 mg daily for three to six months,^{68,69} and among patients in whom there is no response to treatment, a change to danazol, at a dose of 200 mg daily (or only during the luteal phase of the menstrual cycle).⁷⁰ Evening primrose oil has been used, at oral doses of 1 to 3 g daily, on the basis of two randomized studies,^{71,72} but recent trials question its efficacy.^{73,74} Gonadotropin-releasing hormone agonists have been used successfully for severe pain.^{75,76}

NONCYCLIC PAIN

When pain is truly arising from the breast, the approach outlined for cyclic pain is used. However, a musculoskeletal cause is present in 40 percent of women referred to specialized mastalgia clinics for pain thought to arise from the breast. In two thirds of women with diffuse chest-wall pain, the condition responds to oral or topical NSAIDs.⁷⁷ Among the remaining patients, 85 percent gain temporary or permanent relief from the use of a combination of anesthetic and steroidal drugs injected into the tender site.⁷⁷

FOCAL LESIONS

Careful examination distinguishes between solitary, discrete, dominant, persistent masses and vague nodularity and thickening. The Society of Surgical Oncology practice guidelines⁷⁸ recommend the following evaluation. In women 35 years of age or younger, all dominant, discrete, palpable lesions require referral to a surgeon. If vague nodularity, thickening, or asymmetric nodularity is present, the examination should be repeated at midcycle after one or two menstrual cycles. If the abnormality resolves, the patient should be reassured, and if it does not, the patient should be referred to a surgeon. Breast imaging may be appropriate. Women older than 35 years of age with a dominant mass should undergo diagnostic mammography (and frequently, ultrasonography)^{51,54,55} and should then be referred to a surgeon. When vague nodularity or thickening is present, mammographic screening is required, with physical examination repeated at midcycle one to two months afterward and referral to a surgeon if the abnormality persists.

Postmenopausal women are referred for surgical consultation after undergoing mammography. For gross cysts, the guidelines suggest fine-needle as-

piration with imaging studies repeated within six months. Nonbloody fluid is discarded, but if the same cyst refills, surgical consultation is warranted. If bloody, the fluid should be sent for cytologic analysis and consultation with a surgeon should be requested.

Usual practice requires the triple test (palpation; mammography, often in conjunction with ultrasonography; and biopsy) for women more than 35 years of age with dominant masses. When the results of mammographic screening are negative but a dominant mass is present, biopsy is required to rule out breast cancer, since lobular carcinoma may not be visible on mammography. Among younger women, mammography may be omitted if the results of ultrasonographic testing and biopsy yield definitive information. Many experts omit biopsy in the evaluation of younger women with lesions characteristic of fibroadenoma on ultrasonography and elect to follow these patients carefully with serial ultrasonography at six-month intervals for a period of two years and once yearly thereafter. Since careful studies have shown that a lesion that appears to be benign on mammography and ultrasonography is benign more than 99 percent of the time, some experienced clinicians opt for follow-up without biopsy.⁵¹⁻⁵⁴ However, other experienced surgeons disagree and believe that all fibroadenomas require diagnostic core needle biopsy or fine-needle aspiration, especially among carriers of a *BRCA* mutation, in whom medullary cancer may be found. Confirmation on biopsy of fibroadenoma eliminates the need for serial ultrasonography. For patients with a diagnosis of atypical ductal hyperplasia on fine-needle aspiration or core needle biopsy, excisional biopsy is required, because more complete resection often changes the diagnosis to ductal carcinoma in situ.

NIPPLE DISCHARGE

A practical algorithm (Fig. 3) divides discharge into two categories according to the presence or absence of galactorrhea (defined as milk production more than one year after weaning or in nulligravid or menopausal women). The presence of a discharge in association with a palpable mass and positive results on mammography or ultrasonography warrants evaluation of the mass. Galactorrhea is considered pathologic if spontaneous. A workup for galactorrhea includes measurement of prolactin and thyrotropin levels and appropriate endocrinologic evaluation and treatment if the levels are ele-

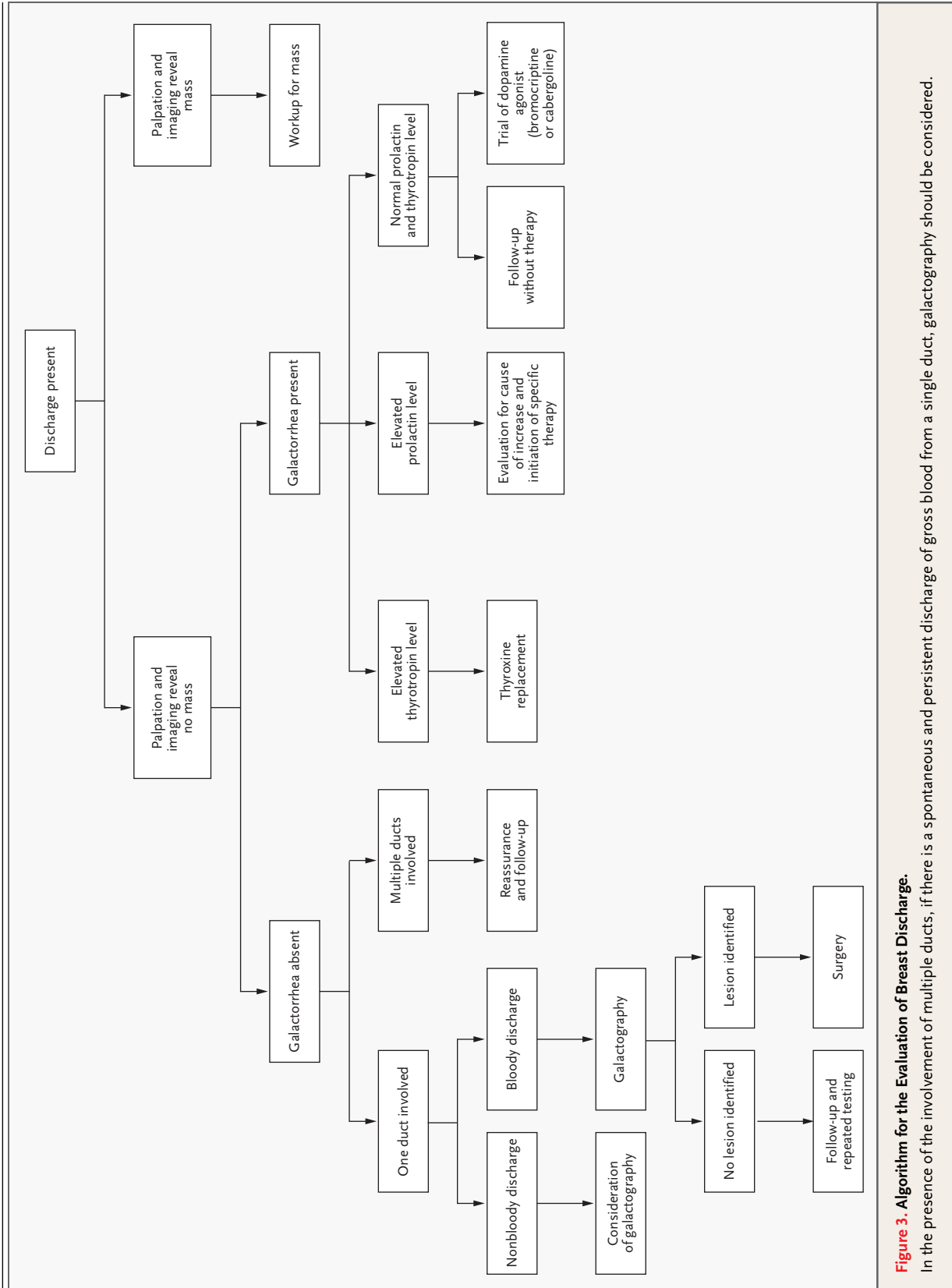


Figure 3. Algorithm for the Evaluation of Breast Discharge.

In the presence of the involvement of multiple ducts, if there is a spontaneous and persistent discharge of gross blood from a single duct, galactography should be considered.

vated.^{79,80} If the levels of both are normal, treatment with dopaminergic agonists may be initiated if the patient desires to reduce the fluid leak.

A discharge in the absence of galactorrhea is considered to be ductal in origin and is classified as either uniductal or multiductal.⁸⁰ When the discharge is from one duct, and particularly if it is grossly bloody or the results of testing for occult blood are positive, a further workup is needed. Galactography with the use of cannulation and insertion of dye into the single duct emitting blood at the nipple allows visualization of a space-occupying lesion. Not all imaging centers have expertise with this technique, and alternatively, surgical biopsy can be used to define the lesion. Direct examination of the ducts by means of mini-fiberoptic endoscopy with a 0.65-mm (outer diameter) cannula (ductoscopy) is currently being evaluated in research centers.⁸¹ Ductal exploration allows the removal of pathologic lesions and cessation of the discharge. Multiductal discharge that is clear, serous, green-black, or nonbloody requires only reassurance of the patient. Blood arising predominantly from one or two ducts should be evaluated further. Lesions that are commonly found are listed in Table 2.

PREVENTION OF BREAST CANCER

Patients with benign breast lesions that impart an increased risk of breast cancer can be offered tamox-

ifen as a preventive strategy. The risk of breast cancer is determined with the use of the Gail model (or among women with a family history that includes second-degree maternal or paternal relatives with breast cancer, the Claus model). Decisions are based on an evaluation of the benefits as compared with the risks of tamoxifen (<http://smi-web.stanford.edu/people/pcheng/breastca>).^{48,49} Risk factors not included in either the Gail or the Claus model include the degree of breast density, plasma levels of free estradiol, bone density, weight gain after menopause, and waist-to-hip ratio.^{44,45,82,83} Current recommendations suggest that women with a five-year risk of breast cancer of more than 1.67 percent and no contraindications to tamoxifen therapy should be informed about the option of taking tamoxifen for five years.⁸⁴⁻⁸⁸ A recent overview of breast-cancer-prevention trials showed a reduction of 50 percent in the relative risk of breast cancer with tamoxifen, but the benefits may be offset by the increased risk of thromboembolic phenomena, endometrial cancer, and the maturation of cataracts.⁸⁸ The ongoing Study of Tamoxifen and Raloxifene (STAR) is addressing whether raloxifene might be preferable to tamoxifen.⁸⁹ More intensive and frequent screening with the use of multimodality imaging (e.g., digital or standard mammography plus ultrasonography or MRI) may be required for high-risk patients.

REFERENCES

- Russo J. Hormonal control of breast development. In: DeGroot LJ, Jameson JL, Burger H, et al., eds. *Endocrinology*. Philadelphia: W.B. Saunders, 2001:2181-8.
- Ginger MR, Gonzalez-Rimbau MF, Gay JP, Rosen JM. Persistent changes in gene expression induced by estrogen and progesterone in the rat mammary gland. *Mol Endocrinol* 2001;15:1993-2009.
- Osborne MP. Breast anatomy and development. In: Harris JR, Osborne CK, Morrow M, Lippman ME, eds. *Diseases of the breast*. Philadelphia: Lippincott Williams & Wilkins, 2000:1-13.
- Potten CS, Watson RJ, Williams GT, et al. The effect of age and menstrual cycle upon proliferative activity of the normal human breast. *Br J Cancer* 1988;58:163-70.
- Hughes LE, Mansel RE, Webster DJ. Aberrations of normal development and involution (ANDI): a new perspective on pathogenesis and nomenclature of benign breast disorders. *Lancet* 1987;2:1316-9.
- Love SM, Gelman RS, Silen W. Fibrocystic "disease" of the breast — a nondisease? *N Engl J Med* 1982;307:1010-4.
- Houssami N, Cheung MN, Dixon JM. Fibroadenoma of the breast. *Med J Aust* 2001;174:185-8.
- Goehring C, Morabia A. Epidemiology of benign breast disease, with special attention to histologic types. *Epidemiol Rev* 1997;19:310-27.
- Dent DM, Hacking EA, Wilkie W. Benign breast disease: clinical classification and disease distribution. *Br J Clin Pract* 1988;42:Suppl:69-71.
- Costantini L, Bucchi L, Dogliotti L, et al. Cohort study of women with aspirated gross cysts of the breast — an update. In: Mansel RE, ed. *Recent developments in the study of benign breast disease*. London: Parthenon, 1993:227-39.
- Sandison AT. An autopsy study of the adult human breast; with special reference to proliferative epithelial changes of importance in the pathology of the breast. In: *National Cancer institute monograph 8*. Washington, D.C.: Government Printing Office, 1962:1-90.
- Is 'fibrocystic disease' of the breast precancerous? *Arch Pathol Lab Med* 1986;110:171-3.
- Hartmann LC, Sellers TA, Frost MH, et al. Benign breast disease and the risk of breast cancer. *N Engl J Med* 2005;353:229-37.
- Shaban AM, Sloane JP, West CR, et al. Histopathologic types of benign breast lesions and the risk of breast cancer: case-control study. *Am J Surg Pathol* 2002;26:421-30.
- Rohan TE, Miller AB. Hormone replacement therapy and risk of benign proliferative epithelial disorders of the breast. *Eur J Cancer Prev* 1999;8:123-30.
- Tan-Chiu E, Wang J, Costantino JP, et al. Effects of tamoxifen on benign breast disease in women at high risk for breast cancer. *J Natl Cancer Inst* 2003;95:302-7.
- Roger P, Sahla ME, Makela S, Gustafsson JA, Baldet P, Rochefort H. Decreased ex-

- pression of estrogen receptor beta protein in proliferative preinvasive mammary tumors. *Cancer Res* 2001;61:2537-41.
18. Allred DC, Mohsin SK. Biological features of human premalignant breast disease. In: Harris JR, Osborne CK, Morrow M, Lippman ME, eds. *Diseases of the breast*. Philadelphia: Lippincott Williams & Wilkins, 2000:355-66.
19. O'Connell P, Pekkel V, Fuqua SA, Osborne CK, Clark GM, Allred DC. Analysis of loss of heterozygosity in 399 premalignant breast lesions at 15 genetic loci. *J Natl Cancer Inst* 1998;90:697-703.
20. Allred DC, Mohsin SK, Fuqua SA. Histological and biological evolution of human premalignant breast disease. *Endocr Relat Cancer* 2001;8:47-61.
21. Lundin C, Mertens F. Cytogenetics of benign breast lesions. *Breast Cancer Res Treat* 1998;51:1-15.
22. Micale MA, Visscher DW, Gulino SE, Wolman SR. Chromosomal aneuploidy in proliferative breast disease. *Hum Pathol* 1994;25:29-35.
23. Hoogerbrugge N, Bult P, de Widt-Levert LM, et al. High prevalence of premalignant lesions in prophylactically removed breasts from women at hereditary risk for breast cancer. *J Clin Oncol* 2003;21:41-5.
24. Boone CW, Kelloff GJ, Freedman LS. Intraepithelial and postinvasive neoplasia as a stochastic continuum of clonal evolution, and its relationship to mechanisms of chemopreventive drug action. *J Cell Biochem Suppl* 1993;17G:14-25.
25. Bardelli A, Parsons DW, Silliman N, et al. Mutational analysis of the tyrosine kinase in colorectal cancers. *Science* 2003;300:949.
26. Preece PE, Mansel RE, Bolton PM, Hughes LM, Baum M, Gravelle IH. Clinical syndromes of mastalgia. *Lancet* 1976;2:670-3.
27. Khan SA, Apkarian AV. The characteristics of cyclical and non-cyclical mastalgia: a prospective study using a modified McGill Pain Questionnaire. *Breast Cancer Res Treat* 2002;75:147-57.
28. Ader DN, South-Paul J, Adera T, Deuster PA. Cyclical mastalgia: prevalence and associated health and behavioral factors. *J Psychosom Obstet Gynecol* 2001;22:71-6.
29. Kessel B. Premenstrual syndrome: advances in diagnosis and treatment. *Obstet Gynecol Clin North Am* 2000;27:625-39.
30. Goodwin PJ, Miller A, Del Giudice ME, Ritchie K. Breast health and associated premenstrual symptoms in women with severe cyclic mastopathy. *Am J Obstet Gynecol* 1997;176:998-1005.
31. Ader DN, Browne MW. Prevalence and impact of cyclic mastalgia in a United States clinic-based sample. *Am J Obstet Gynecol* 1997;177:126-32.
32. Goodwin PJ, Neelam M, Boyd NF. Cyclical mastopathy: a critical review of therapy. *Br J Surg* 1988;75:837-44.
33. Santen R, Pinkerton J. Benign breast disorders. In: DeGroot LJ, Jameson JL, Burger H, et al., eds. *Endocrinology*. Philadelphia: W.B. Saunders, 2002:2189-98.
34. Ambrogetti D, Berni D, Catarzi S, Ciatto S. The role of ductal galactography in the differential diagnosis of breast carcinoma. *Radiol Med (Torino)* 1996;91:198-201. (In Italian.)
35. Seltzer MH, Perloff LJ, Kelley RI, Fitts WT Jr. The significance of age in patients with nipple discharge. *Surg Gynecol Obstet* 1970;131:519-22.
36. Dupont WD, Parl FF, Hartmann WH, et al. Breast cancer risk associated with proliferative breast disease and atypical hyperplasia. *Cancer* 1993;71:1258-65.
37. London SJ, Connolly JL, Schnitt SJ, Colditz GA. A prospective study of benign breast disease and the risk of breast cancer. *JAMA* 1992;267:941-4. [Erratum, *JAMA* 1992;267:1780.]
38. Wang J, Costantino JP, Tan-Chiu E, Wickerham DL, Paik S, Wolmark N. Lower-category benign breast disease and the risk of invasive breast cancer. *J Natl Cancer Inst* 2004;96:616-20.
39. Wolfe JN, Saftlas AF, Salane M. Mammographic parenchymal patterns and quantitative evaluation of mammographic densities: a case-control study. *AJR Am J Roentgenol* 1987;148:1087-92.
40. Boyd NF, Jensen HM, Cooke G, Han HL, Lockwood GA, Miller AB. Mammographic densities and the prevalence and incidence of histological types of benign breast disease. *Eur J Cancer Prev* 2000;9:15-24.
41. Byrne C, Schairer C, Brinton LA, et al. Effects of mammographic density and benign breast disease on breast cancer risk (United States). *Cancer Causes Control* 2001;12:103-10.
42. Boyd NF, Dite GS, Stone J, et al. Heritability of mammographic density, a risk factor for breast cancer. *N Engl J Med* 2002;347:886-94.
43. Hankinson SE, Willett WC, Manson JE, et al. Plasma sex steroid hormone levels and risk of breast cancer in postmenopausal women. *J Natl Cancer Inst* 1998;90:1292-9.
44. Key T, Appleby P, Barnes I, Reeves G, Endogenous Hormones and Breast Cancer Collaborative Group. Endogenous sex hormones and breast cancer in postmenopausal women: reanalysis of nine prospective studies. *J Natl Cancer Inst* 2002;94:606-16.
45. Hulka BS, Moorman PG. Breast cancer: hormones and other risk factors. *Maturitas* 2001;38:103-13.
46. Antoniou A, Pharoah PDP, Narod S, et al. Average risks of breast and ovarian cancer associated with BRCA1 or BRCA2 mutations detected in case series unselected for family history: a combined analysis of 22 studies. *Am J Hum Genet* 2003;72:1117-30. [Erratum, *Am J Hum Genet* 2003;73:709.]
47. Dooley WC, Ljung BM, Veronesi U, et al. Ductal lavage for detection of cellular atypia in women at high risk for breast cancer. *J Natl Cancer Inst* 2001;93:1624-32.
48. Gail MH, Brinton LA, Byar DP, et al. Projecting individualized probabilities of developing breast cancer for white females who are being examined annually. *J Natl Cancer Inst* 1989;81:1879-86.
49. McTiernan A, Kuniyuki A, Yasui Y, et al. Comparisons of two breast cancer risk estimates in women with a family history of breast cancer. *Cancer Epidemiol Biomarkers Prev* 2001;10:333-8.
50. Barton MB, Harris R, Fletcher SW. Does this patient have breast cancer? *JAMA* 1999;282:1270-80.
51. Shetty MK, Shah YP, Sharman RS. Prospective evaluation of the value of combined mammographic and sonographic assessment in patients with palpable abnormalities of the breast. *J Ultrasound Med* 2003;22:263-8.
52. Moy L, Slanetz PJ, Moore R, et al. Specificity of mammography and US in the evaluation of a palpable abnormality: retrospective review. *Radiology* 2002;225:176-81.
53. Soo MS, Rosen EL, Baker JA, Vo TT, Boyd BA. Negative predictive value of sonography with mammography in patients with palpable breast lesions. *AJR Am J Roentgenol* 2001;177:1167-70.
54. Flobbe K, Bosch AM, Kessels AG, et al. The additional diagnostic value of ultrasonography in the diagnosis of breast cancer. *Arch Intern Med* 2003;163:1194-9.
55. Venta LA. Image-guided biopsy of nonpalpable breast lesions. In: Harris JR, Lippman ME, Morrow M, Osborne CK, eds. *Diseases of the breast*. 2nd ed. Philadelphia: Lippincott Williams & Wilkins, 2000:149-64.
56. Groves AM, Carr M, Wadhwa V, Leonard TWJ. An audit of cytology in the evaluation of nipple discharge: a retrospective study of 10 years' experience. *Breast* 1996;5:96-9.
57. Gateley CA, Miers M, Mansel RE, Hughes LE. Drug treatments for mastalgia: 17 years experience in the Cardiff Mastalgia Clinic. *J R Soc Med* 1992;85:12-5.
58. Hughes LE, Mansel RE, Webster DJT. *Benign breast disorders and diseases of the breast*. 2nd ed. London: W.B. Saunders, 1999.
59. Cuzick J, Forbes J, Edwards R, et al. First results from the International Breast Cancer Intervention Study (IBIS-I): a randomised prevention trial. *Lancet* 2002;360:817-24.
60. Wilson MC, Sellwood RA. Therapeutic value of a supporting brassiere in mastodynia. *Br Med J* 1976;2:90.
61. Charreau I, Plu-Bureau, Bachelot A, Contesso G, Guinebretiere JM, Le MG. Oral contraceptive use and risk of benign breast disease in a French case-control study of young women. *Eur J Cancer Prev* 1993;2:147-54.
62. Mauvais-Jarvis P. Mastodynia and fibrocystic disease. *Curr Ther Endocrinol Metab* 1988;3:280-4.

63. Millet AV, Dirbas FM. Clinical management of breast pain: a review. *Obstet Gynecol Surv* 2002;57:451-61.
64. BeLieu RM. Mastodynia. *Obstet Gynecol Clin North Am* 1994;21:461-77.
65. Zylstra S. Office management of benign breast disease. *Clin Obstet Gynecol* 1999;42:234-48.
66. Steinbrunn BS, Zera RT, Rodriguez JL. Mastalgia: tailoring treatment to type of breast pain. *Postgrad Med* 1997;102:183-4.
67. Wetzig NR. Mastalgia: a 3 year Australian study. *Aust N Z J Surg* 1994;64:329-31.
68. Fentiman IS, Caleffi M, Brame K, Chaudary MA, Hayward JL. Double-blind controlled trial of tamoxifen therapy for mastalgia. *Lancet* 1986;1:287-8.
69. Messinis IE, Lolis D. Treatment of premenstrual mastalgia with tamoxifen. *Acta Obstet Gynecol Scand* 1988;67:307-9.
70. O'Brien PM, Abukhalil IE. Randomized controlled trial of the management of premenstrual syndrome and premenstrual mastalgia using luteal phase-only danazol. *Am J Obstet Gynecol* 1999;180:18-23.
71. Pashby NL, Mansel RE, Hughes LE, Hanslip JJ, Preece P. A clinical trial of evening primrose oil in mastalgia. *Br J Surg* 1981;68:801-24.
72. Preece PE, Hanslip JJ, Gilbert L. Evening primrose oil (Efamol) for mastalgia. In: Horrobin DF, ed. *Clinical uses of essential fatty acids*. Montreal: Eden Press, 1982:147-54.
73. Goyal A, Mansel RE, Efamast Study Group. A randomized multicenter study of gamolenic acid (Efamast) with or without antioxidants, vitamins and minerals in the management of mastalgia. *Breast J* 2005;11:41-7.
74. Blommers J, de Lange-De Klerk ES, Kuik DJ, Bezemer PD, Meijer S. Evening primrose oil and fish oil for severe chronic mastalgia: a randomized, double-blind, controlled trial. *Am J Obstet Gynecol* 2002;187:1389-94.
75. Hamed H, Caleffi M, Chaudary MA, Fentiman IS. LHRH analogue for treatment of recurrent and refractory mastalgia. *Ann R Coll Surg Engl* 1990;72:221-4.
76. Mansel RE, Goyal A, Preece P, et al. European randomized, multicenter study of goserelin (Zoladex) in the management of mastalgia. *Am J Obstet Gynecol* 2004;191:1942-9.
77. Kollias J, Sibbering DM, Blamey RW. Topical non-steroidal anti-inflammatory gel for diffuse chest wall pain in mastalgia patients. In: Mansel RE, ed. *Recent developments in the study of benign breast disease*. London: Parthenon Publishing, 1997:119-24.
78. Morrow M, Bland KI, Foster R. Breast cancer surgical practice guidelines: Society of Surgical Oncology practice guidelines. *Oncology (Huntingt)* 1997;11:877-81.
79. Mah PM, Webster J. Hyperprolactinemia: etiology, diagnosis, and management. *Semin Reprod Med* 2002;20:365-74.
80. Falkenberg SS. Nipple discharge. *Obstet Gynecol Clin North Am* 2002;29:21-9.
81. Mokbel K, Elkak AE. The evolving role of mammary ductoscopy. *Curr Med Res Opin* 2002;18:30-2.
82. Boyd NF, Lockwood GA, Byng JW, Tritchler DL, Yaffe MJ. Mammographic densities and breast cancer risk. *Cancer Epidemiol Biomarkers Prev* 1998;7:1133-44.
83. Kuller LH, Cauley JA, Lucas L, Cummings S, Browner WS. Sex steroid hormones, bone mineral density, and risk of breast cancer. *Environ Health Perspect* 1997;105:Suppl 3:593-9.
84. Chlebowski RT, Collyar DE, Somerfield MR, Pfister DG. American Society of Clinical Oncology technology assessment on breast cancer risk reduction strategies: tamoxifen and raloxifene. *J Clin Oncol* 1999;17:1939-55.
85. Chlebowski RT, Col N, Winer EP, et al. American Society of Clinical Oncology technology assessment of pharmacologic interventions for breast cancer risk reduction including tamoxifen, raloxifene, and aromatase inhibition. *J Clin Oncol* 2002;20:3328-43.
86. Gail MH, Costantino JP, Bryant J, et al. Weighing the risks and benefits of tamoxifen treatment for preventing breast cancer. *J Natl Cancer Inst* 1999;91:1829-46. [Erratum, *J Natl Cancer Inst* 2000;92:275.]
87. Levine M, Moutquin JM, Walton R, Feightner J. Chemoprevention of breast cancer: a joint guideline from the Canadian Task Force on Preventive Health Care and the Canadian Breast Cancer Initiative's Steering Committee on Clinical Practice Guidelines for the Care and Treatment of Breast Cancer. *CMAJ* 2001;164:1681-90.
88. Cuzick J, Powles T, Veronesi U, et al. Overview of the main outcomes in breast-cancer prevention trials. *Lancet* 2003;361:296-300.
89. Pappas SG, Jordan VC. Chemoprevention of breast cancer: current and future prospects. *Cancer Metastasis Rev* 2002;21:311-21.

Copyright © 2005 Massachusetts Medical Society.

FULL TEXT OF ALL JOURNAL ARTICLES ON THE WORLD WIDE WEB

Access to the complete text of the *Journal* on the Internet is free to all subscribers. To use this Web site, subscribers should go to the *Journal's* home page (www.nejm.org) and register by entering their names and subscriber numbers as they appear on their mailing labels. After this one-time registration, subscribers can use their passwords to log on for electronic access to the entire *Journal* from any computer that is connected to the Internet. Features include a library of all issues since January 1993 and abstracts since January 1975, a full-text search capacity, and a personal archive for saving articles and search results of interest. All articles can be printed in a format that is virtually identical to that of the typeset pages. Beginning six months after publication, the full text of all Original Articles and Special Articles is available free to nonsubscribers who have completed a brief registration.